


<h2>Diagnostic Approach and Management of Extrauterine Pregnancy</h2>		<b>Healthcare</b>
		<b>Keywords:</b> Ectopic pregnancy, diagnosis, ultrasound examination, management, complication.

<b>Helidon Klosi</b>	Obstetrician and Gynecologist. University Hospital of Obstetrics and Gynecology, Tirana. Bajram Curri Boulevard, Elbow, Tirana, Albania.
<b>Rustem Celami</b> Corresponding author	Obstetrician and Gynecologist. University Hospital of Obstetrics and Gynecology, Tirana. Bajram Curri Boulevard, Elbow, Tirana, Albania.
<b>Genc Kabili</b>	Obstetrician and Gynecologist. University Hospital of Obstetrics and Gynecology, Tirana. Bajram Curri Boulevard, Elbow, Tirana, Albania.
<b>Dritan Deçka</b>	Obstetrician and Gynecologist. University Hospital of Obstetrics and Gynecology, Tirana. Bajram Curri Boulevard, Elbow, Tirana, Albania.
<b>Edlira Klosi</b>	Obstetrician and Gynecologist, Health Authority of Tirana Region.

**Abstract**

An ectopic pregnancy is a pregnancy that develops outside a woman's uterus. This happens when the fertilized egg from the ovary does not reach or implant itself normally in the uterus. Instead, the egg develops somewhere else in the abdomen. The products of this conception are abnormal and cannot develop into fetuses. Urine pregnancy test is often done by women itself once amenorrhea is present about 2 weeks of expected menstrual period, however, pregnancy blood test such Beta – human Chorionic Gonadotropin (hCG) and ultrasound examination are the best tool of diagnosis. The most common place that ectopic pregnancy occurs is in one of the fallopian tubes, a so-called tubal pregnancy. These are the tubes that transport the egg from the ovary to the uterus. Ectopic pregnancies also can be found on the outside of the uterus, on the ovaries, or attached to the bowel. Most serious complication of an ectopic pregnancy is intra-abdominal hemorrhage. In the case of a tubal pregnancy, for example, as the products of conception continue to grow in the fallopian tube, the tube expands and eventually ruptures. This can be very dangerous because a large artery runs on the outside of each Fallopian tube. If the artery ruptures, the woman can bleed severely. Ectopic pregnancy is usually found in the first 5-10 weeks of pregnancy and is the leading cause of pregnancy-related deaths in the first trimester of pregnancy in the USA. In Albania, we face difficulties not only in application of high technology of ultrasound machine in public health sector but unfortunately we are unable to perform hCG in public health sector laboratories, such making not only challenge and even delay but an expensive process of diagnosis of this medical problem. In conclusion, since ectopic pregnancy is an abnormal pregnancy, and comes with high risk of serious complication, early diagnosis of pregnancy location and its management is crucial in preventing medical complication.

**Introduction**

Clinicians should consider the diagnosis of ectopic pregnancy in any woman in the first trimester of pregnancy who has abdominal or pelvic pain, vaginal bleeding, or both. Ectopic pregnancy is the most common cause of pregnancy-related death in the first trimester and accounts for about 10% of all pregnancy-related deaths. Missed ectopic pregnancy is a leading cause of emergency medicine malpractice claims.

Differentiating ectopic pregnancy from early normal or abnormal intrauterine pregnancy can be a clinical dilemma. Pregnancy of unknown location (PUL) is a term used when a pregnancy test is positive, but ultrasound examination (U/S) does not show evidence of either an intrauterine or an ectopic pregnancy. Schematic illustration of ectopic pregnancy in figure 1. Careful evaluation of the pregnancy of unknown location is important since ectopic pregnancy represent 1% to 2% of all USA pregnancies and approximately 30 to 40 women die annually in the United States from ectopic pregnancy-associated hemorrhage.<sup>1,2</sup> Although the rate of death associated with ectopic pregnancy has declined in recent years, there are still racial disparities in mortality that may be associated with lack of access to healthcare.<sup>2,3</sup>

Thus, careful evaluation of these patients is warranted. Sensitive urine tests will detect pregnancies well before they are visible on U/S. Therefore, pregnancy of unknown location has become a frequent diagnosis. A recent consensus statement highlighted regional differences in use of the terminology and argued for more consistent uniform classification.<sup>4</sup>

That summary emphasized that pregnancy of unknown location is an initial descriptive term that should eventually result in a final diagnosis of one of the following: ectopic pregnancy, intrauterine pregnancy (IUP), resolved pregnancy of unknown location, or treated pregnancy of unknown location. Accurate classification is important in research settings in order to standardize result reporting. In clinical practice it is essential in guiding appropriate treatment. Ultrasound examination illustration of ectopic pregnancy in figure 2.

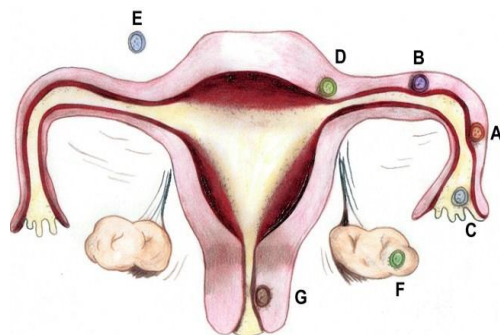


Figure 1.

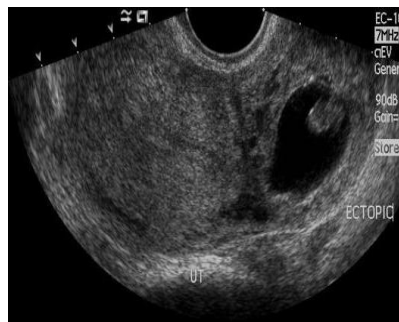

Figure 2.

Figure 1. Sites and frequencies of ectopic pregnancy. (A) Ampullary, 80%; (B) Isthmic, 12%; (C) Fimbrial, 5%; (D) Cornual/Interstitial, 2%; (E) Abdominal, 1.4%; (F) Ovarian, 0.2%; and (G) Cervical, 0.2%. According to American College of Obstetricians and Gynecologists (ACOG).

Figure 2. Illustration of ectopic pregnancy/extra uterine pregnancy by ultrasound examination.

### Discussion

Judging the duration of pregnancy guides the clinician's interpretation of laboratory and imaging studies. Historical factors can be helpful in assessing gestational age; however, accuracy of recollection of last menstrual period is not consistent. A recent study looking at women seeking elective abortion found that women underestimated gestational age by 1.2 weeks, and that greater gestational age was associated with more inaccuracy.<sup>5</sup> Other studies have shown that last menstrual period overestimates gestational age and that accuracy of recall declines with duration since last menstrual period.<sup>6-8</sup> A sometimes-overlooked factor in assessing duration of pregnancy is the patient's sexual history and self-perceived estimate of when conception occurred.

At this point in the evaluation, this patient can be described as having a pregnancy of unknown location. It is not a definitive diagnosis, but rather a description that should help guide evaluation that will result in a more specific diagnosis. Pregnancy of unknown location is not meant to describe the patient with presumed ectopic pregnancy based on U/S findings of a suspicious adnexal mass, nor does it include a patient in whom a sac-like structure without yolk sac is visualized (a suspected IUP). A pregnancy of unknown location can represent a nonvisualized ectopic pregnancy, an abnormal IUP, or an early normal IUP. Distinguishing among these entities is sometimes a clinical challenge.

An important concept in evaluating a patient in this situation is the discriminatory value. This refers to the value of beta human chorionic gonadotropin (hCG) above which U/S should be diagnostic of an IUP. The discriminatory value is both user- and equipment-dependent. It should be considered a relative concept.<sup>12</sup> Uterine malposition or malformation, the presence of fibroids, and patient obesity can all affect the quality of imaging. Most algorithms in use suggest that, if a normal IUP is present, it would be detected on U/S when the hCG level is 2000 or more.<sup>13</sup> This assumes a singleton IUP. In multiple gestations, the hCG will be higher at any particular point in gestation. Moreover, in an early loss of a twin, the hCG could plateau and then rise.

Additionally, a recently published analysis of one center's experience described a patient with hCG of 2317 with no IUP visualization who went on to develop a normal pregnancy. The authors modeled the association of hCG and visualization of the gestational sac and found the probability of detecting a sac would be 99% at a beta of 3510, suggesting that the discriminatory value in their institution may be higher and that the concept should be used cautiously.<sup>14</sup> An accurate assessment of gestational age based on dates is a better predictor of U/S landmarks than is a single measurement of hCG. In the stable patient with an hCG below the discriminatory value, serial hCG follow-up may be useful in evaluation of a pregnancy of unknown location.

Progesterone levels have also been used to evaluate pregnancy of unknown location. Initially, it was felt that a progesterone level of < 5 ng/mL was likely to indicate an abnormal pregnancy.<sup>13</sup> However, there are reported cases of viable pregnancies with progesterone lower than this level and ectopic pregnancies with normal progesterone levels. Moreover, the availability of the assay is not immediate, and thus a progesterone level is of limited clinical use.

Ultrasound of a symptomatic patient in early pregnancy requires careful examination of not only the endometrial cavity, but also the adnexa. The sensitivity of U/S in detecting ectopic pregnancy is dependent upon the skill of the sonographer. Its positive predictive value will depend upon the underlying likelihood of an ectopic pregnancy in the population being evaluated.

Ultrasound examination requires not only experienced high level skills of examiner but also the application of modern technology. In Albania, we face difficulties not only in application of high technology of ultrasound machine in public medical system but unfortunately we are unable to order hCG in public health laboratories, such making not only challenge and even delay but an expensive process of diagnosis of this medical problem.

A recent study reported one center's experience using transvaginal U/S performed by residents in obstetrics and gynecology. In patients presenting with symptoms who were eventually diagnosed as having ectopic pregnancies, 61% had nondiagnostic U/S.<sup>14, 15</sup> In contrast, in an early pregnancy unit with specialized sonographers, an initial U/S was able to detect 74% of ectopic pregnancies with 99% specificity.<sup>13, 14, 15</sup>

Endometrial thickness cannot differentiate ectopic pregnancy from either viable or nonviable IUP.<sup>12, 13</sup> The presence of free fluid in the posterior cul-de-sac is also not diagnostic of ectopic pregnancy. However, it may be caused by rupture or bleeding of the fallopian tube. A subjective assessment of the amount of fluid and whether it appears clear or echogenic can guide the clinician regarding the likelihood of hemoperitoneum.

In the case of suspected or obvious rupture, surgical intervention using the laparoscopic approach is warranted. In cases of hemodynamic instability, laparotomy is indicated. The decision to perform salpingectomy or salpingostomy is initially based on feasibility of the more conservative approach. If the tube is badly damaged or has been the site of a previous ectopic pregnancy, it should be removed. If unruptured, as in this case, salpingostomy can be considered. Expert opinion suggests that in the presence of a diseased or absent contralateral tube, salpingostomy is the preferred approach to maximize the potential for future fertility. Controversy has surrounded the choice between salpingostomy and salpingectomy in the patient with a normal contralateral tube. This debate centers on future reproductive outcome, including both fertility and risk of recurrent ectopic pregnancy.

A recent population-based study prospectively examined the cumulative rates of IUP for women who had undergone ectopic treatment.<sup>210, 11, 13</sup> In multivariate analysis, there was no difference in fertility among women who underwent salpingectomy, salpingostomy, or medical treatment. Moreover, the rate of repeat ectopic pregnancy did not differ. However, a subgroup of women who were 35 or older with a history of infertility or tubal disease seemed to benefit from conservative surgery. Prior research has also failed to clearly favor 1 approach more than the other.<sup>16, 17</sup> A major disadvantage of salpingostomy is the risk of persistent ectopic tissue. Ten percent to 15% of patients will require additional medical or surgical treatment.<sup>17</sup>

Expectant management is sometimes appropriate in asymptomatic women. ACOG suggests this can be considered in women with initial low and dropping hCG levels.<sup>18</sup> A recent randomized trial compared expectant management to single-dose methotrexate in women with ectopic pregnancies (defined as either positive findings on U/S with plateaued hCG less than 1500 or a PUL with plateaued hCG less than 2000).<sup>18</sup> Sixty percent of women in the expectant management group and 76% of those in the methotrexate group required no additional treatment. Two percent of the methotrexate group and 13% of the expectant management group required surgery. Another less-rigorously designed trial evaluated a cohort of women treated for ectopic pregnancy.<sup>19</sup> In that study, 49% of women managed expectantly did not require other treatment. An ongoing trial is randomizing women to either methotrexate or placebo.<sup>20</sup>

Patients treated with salpingostomy, methotrexate, or expectant management all need careful follow-up because of the potential for persistent growth of trophoblastic tissue and risk of tubal rupture. The hCG is expected to drop by 15% between days 4 and 7 after methotrexate is administered. Patients who have received methotrexate and those who have undergone salpingostomy should be followed weekly until resolution. Surveillance of those managed expectantly is generally more frequent in the initial week, with repeat hCG levels every 2 to 4 days and then weekly.

In recommending treatment options, the need for frequent follow-up should be considered carefully in light of the patient's individual circumstances. Two reports in the literature examined compliance with follow-up in inner-city populations. One found that only 10% of patients completely complied and 15% were lost to follow-up despite rigorous attempts to reach them.<sup>29</sup> The other study had an 11% complete loss to follow-up. Only 45% were followed to the point of a negative hCG.<sup>30, 31</sup> Women with demonstrated noncompliance or lack of ready access to care may be better served by salpingectomy.

## Conclusions

In conclusion, ectopic pregnancy can be a life-threatening condition. Careful attention to patient history, with judicious use of U/S and hCG levels, should guide diagnosis. Once ectopic pregnancy is diagnosed, treatment options should be considered carefully, taking into account the patient's reproductive plans and ability to comply with follow-up.

**References**

1. Kobayashi M, Hellman LM, Fillisti LP. Ultrasound. An aid in the diagnosis of ectopic pregnancy. *Am J Obstet Gynecol* 1969; 103: 1131–1140.
2. Shalev E, et al. Transvaginal sonography as the ultimate diagnostic tool for the management of ectopic pregnancy: experience with 840 cases. *Fertil Steril* 1998; 69: 62–65.
3. de Crespigny LC. Demonstration of ectopic pregnancy by transvaginal ultrasound. *Br J Obstet Gynaecol* 1988; 95: 1253–1256.
4. Sawyer E, et al. The value of measuring endometrial thickness and volume on transvaginal ultrasound scan for the diagnosis of incomplete miscarriage. *Ultrasound Obstet Gynecol* 2007; 29: 205–209.
5. Barnhart K, et al. Pregnancy of unknown location: a consensus statement of nomenclature, definitions, and outcome. *Fertil Steril*. 2011 Mar 1;95(3):857-66.
6. Fleischer AC, et al. Ectopic pregnancy: features at transvaginal sonography. *Radiology* 1990; 174: 375–378.
7. Timor-Tritsch I. Relevant pelvic anatomy. In *Ultrasound in Gynecology*, Goldstein S, Timor-Tritsch I (eds). Churchill Livingstone: Philadelphia, 2007; 53.
8. Timor-Tritsch IE, Farine D, Rosen MG. A close look at early embryonic development with the high-frequency transvaginal transducer. *Am J Obstet Gynecol* 1988; 159: 676–681.
9. Chang FW, Chen CH, Liu JY. Early diagnosis of ovarian pregnancy by ultrasound. *Int J Gynaecol Obstet* 2004; 85: 186–187.
10. Tay JI, Moore J, Walker JJ. Ectopic pregnancy. *BMJ* 2000; 320: 916–919.
11. Hofmann HM, et al. Cervical pregnancy: case reports and current concepts in diagnosis and treatment. *Arch Gynecol Obstet* 1987; 241: 63–69.
12. Bouyer J, et al. Sites of ectopic pregnancy: a 10 year population-based study of 1800 cases. *Hum Reprod* 2002; 17: 3224–3230.
13. Chen, G.-D., Lin, M.-T. and Lee, M.-S. (1994), Diagnosis of interstitial pregnancy with sonography. *J. Clin. Ultrasound*, 22: 439–442.
14. Turkia Abu Halima and Khalida Javaid, 2011. Pregnancy in Rudimentary Horn of Uterus: A Case Report. *Research Journal of Obstetrics and Gynecology*, 4: 37-41.
15. DeNicola RR, Peterson MR. Pregnancy in rudimentary horn of uterus. *Am J Surg* 1947; 73: 382–386.
16. Ackerman TE, Levi CS, Dashefsky SM, Holt SC, Lindsay DJ. Interstitial line: sonographic finding in interstitial (cornual) ectopic pregnancy. *Radiology* 1993; 189: 83–87.
17. Timor-Tritsch IE, Monteagudo A, Matera C, Veit CR. Sonographic evolution of cornual pregnancies treated without surgery. *Obstet Gynecol* 1992; 79: 1044–1049.
18. Breen JL. A 21 year survey of 654 ectopic pregnancies. *Am J Obstet Gynecol* 1970; 106: 1004–1019.
19. Hoover KW, Tao G, Kent CK. Trends in the diagnosis and treatment of ectopic pregnancy in the United States. *Obstet Gynecol*. Mar 2010;115(3):495-502.
20. Stovall TG, Ling FW, Gray LA. Single-dose methotrexate for treatment of ectopic pregnancy. *Obstet Gynecol*. May 1991;77(5):754-7.