

Impact of Echocardiography in Diagnosis Heart Lesion after Rheumatic Fever Disease in Kosovar Children



Healthcare

Keywords: rheumatic fever, rheumatic heart disease, chorea minor, echocardiography.

Ramush A. Bejiqi	Pediatric Clinic, University Clinical Center of Kosovo, Prishtina, Republic of Kosovo.
Ragip Retkoceri	Pediatric Clinic, University Clinical Center of Kosovo, Prishtina, Republic of Kosovo.
Hana Bejiqi	Main Center of Family Medicine, Prishtina, Republic of Kosovo.

Abstract

Background: Acute rheumatic fever and its sequels, rheumatic heart diseases, remain major unsolved preventable health problems in Kosovo population, particularly among the disadvantages indigenous Albanian and Egyptians people. In Kosovo, despite of performing secondary prophylaxis with benzathine penicillin, acute rheumatic fever hospitalization rates have remained essentially unchanged for the last 20 years. The role of echocardiography in the diagnosis of acute rheumatic carditis was established over the last 20 years. Aims In this study we aimed to determine the prevalence of rheumatic heart disease in children from Kosovo population with the first attack of acute rheumatic fever. Also, we presented that echocardiography examination detects a greater prevalence of rheumatic heart disease than other diagnostic procedures. We aimed to compare the sensitivity and specificity of cardiac auscultation, ECG record, lab analysis to echocardiography and to determine the feasibility of specific age in this setting. MethodsTo optimize accurate diagnosis of rheumatic fever and rheumatic heart disease, we utilized two group models. In the first group of 388 children who were hospitalized and treated before 1999, diagnosis of rheumatic fever was decided basing on the clinical and laboratory findingswhereas in second group (221 children treated from1999 to 2010), clinical and lab diagnosis were amplified also on the detection by echocardiography. ConclusionIn second group, using echocardiography as a method of diagnosis and assessment children with rheumatic fever, we found high rates of undetected rheumatic heart disease in this high-risk group population. Echocardiographic examination of children with rheumatic fever for rheumatic heart disease may over-diagnose rheumatic heart disease unless congenital mitral valve anomalies and physiological regurgitation are excluded.

Introduction

Acute migratory polyarthritis, then known as “acute articular rheumatism” was the first manifestation described simultaneously in 1605, in France byGuillaume de Baillou and in England by Thomas Sydenham. The following year he described the disorder of movement (St Vitus dance) that is now called Sydenham’s chorea. The clinical manifestations of rheumatic fever were described in the latter half of 17th century.The full clinical syndrome was appreciated only near the end of the 19th century.In 1944 Thomas Duckett Jones proposed a set of guidelines for the diagnosis of rheumatic fever, now known as the Jones’ criterions. (1, 2, 3, 4,) Rheumatic fever is now considered an acute non-suppurative inflammatory disease that follows group A Streptococcal infection of the throat. (5, 6)

At the beginning of the 21st century, and 400 years after the first description, it has remained the most common cause of acquired heart disease in underdevelopment countries, in children and young adults. It has continued to be a major public health problem worldwide, but particularly in developing countries. In 1990, the World Health Organization estimated that 12 million people are affected, with more than 400 000 deaths occurring annually and with hundreds of thousands more, mainly children, left disabled. Although the incidence has declined significantly in developed countries, rheumatic fever is relatively uncommon in North America and in the most European Countries but is still often in some Balkans countries, including Kosovo too. The consequences of acute rheumatic fever remain significant: approximately 80 % of patients have cardiac involvement with clinical and subclinical carditis during their acute episode and 35 % go on to develop moderate or severe rheumatic heart disease. Rheumatic heart disease result in considerable expanses to the health system and personal cost to patients whose career choices, quality of life; medical and surgical treatment and fertility are adversely affected. Rheumatic mitral stenosis is common in such children and adults, many times without a history of rheumatic fever in previous period. (6, 7, 8)

Kosovo is the youngest country in the world, with the youngest population in Europe, where 50 % of citizens are younger than 25 years. In the same time Kosovo was the most underdevelopment countrywhen it

was a part of Yugoslavia, with a very low level of social and health care services. All of these issues have led to an increase in the incidence of rheumatic fever in that period in Kosovo. (3, 8, 9)

The role of echocardiography in the diagnosis of acute rheumatic carditis was established over the last 20 years. The World Health Organization recommends screening for rheumatic fever and rheumatic carditis in all affected children and in high risk population. The recent availability of compact portable echocardiography has led to the growing use of technology for rheumatic heart disease screening in a number of low-income countries where it is shown to detect significantly more rheumatic heart disease than laboratory analysis and cardiac auscultation. Recent data showed that in those low-income countries the prevalence of rheumatic heart disease varying from 75 per 100,000 children in urban population in South Auckland, 21.5 per 1000 in Cambodia and 42.6 per 1000 in Tonga. (8, 9, 10) Echocardiography detects clinically inaudible yet hemodynamically significant valve lesions, and can exclude pathology in those with an innocent cardiac murmur. After the war in Kosovo we established guidelines for echocardiography screening for all children with or suspected for/with rheumatic fever in order to confirm or exclude the presence of carditis and heart lesions.

Objective

Based on the high incidence of rheumatic fever in Kosovo and the high number of patients with rheumatic heart disease, despite the improvement in prevention and treatment, our objective was to present all children admitted and treated from rheumatic fever in the Pediatric Clinic in Prishtina, during the period 1998 – 2010 and to describe the clinical manifestations and heart lesions, as diagnosed by echocardiography.

Patients and methods

Between January 1988 and December 2010, at Division of Cardiology and Rheumatology 609 patients were admitted with diagnosis of acute rheumatic fever. Diagnosis was based on using the modified Jones' criterions. Patients were divided in two groups: Group I include patients admitted from January 1988 to December 1998 and, Group II, includes patients admitted from January 1999 to December 2010. Criteria for separation was the war in the late '90s and input of the echocardiography as a method for diagnosis and assessment heart lesions. Our study was based on the examination of medical records of 388 patients treated from Group I and on the medical records and echocardiograms of 221 patients from Group II.

A single pediatric cardiologist executed echocardiograms and every patient underwent three or more examinations, with a mean interval of 15 days. Most of the patients have been under and streptococcal prevention, 364 children (93.8%) from first group and 211 (95%) from second group. None of the patients was receiving cardiovascular medications at the time of the echocardiographic examinations.

Before the examination, weight and stature were recorded and the body surface area was calculated by the Dubois and Dubois formula. Also, blood pressure was measured and 12-lead electrocardiogram record was obtained. In spite of Doppler examination with color-flow mapping, all the echocardiograms were performed at rest, without sedation, and included the M- and two-dimensional modes. The ultrasound systems used were: Acuson Aspen Advanced, Acuson Sequoia 256 and Hewlett Packard 2000 Sonos. The diastolic and systolic diameters were measured using M-mode in the parasternal short axis view. Systolic function and dimensions of the left ventricle were obtained and the ejection fraction was obtained by the Teichholtz method, and values equal to or above 55% were considered normal. The morphological aspect of the valves was evaluated by the two-dimensional echocardiography. The severity of mitral and aortic regurgitation, and mitral and aortic stenosis were determined by color-flow Doppler evaluation and reported according to the recommendations of the American Society of Echocardiography. Gain settings were optimized by the sonographers as the large variation in body habitus precluded the use of standardized settings.

Valve leaflet morphology was assessed in parasternal long and short-axis views. When indicated, echocardiographic measurements were interpreted according to the body surface area.

Results and comments

Global evaluation

From the total number of 609 children included in our study, 388 (63.7%) belong to the Group I, with nearly equal frequency in males and females (311 male or 51% and 298 female or 49%), aged 5 to 17 years, with a median 11 years. All patients were white, 238 (61.3%) were from rural environments and 150 (38.7%) from urban communities. All children underwent careful clinical examination specifically evaluating for manifestations of rheumatic fever e.g. migratory polyarthritis, chorea minor, carditis, rash, cardiomegaly on a chest radiograph and AV-block on the electrocardiogram.

	N. of patients	Male N %	Female N %	Arthritis N %	Carditis N %	Ch.minor N %	N.subcut. N %	E. margi. N %
1988	38	20 (52.6)	18 (47.4)	32 (84.2)	31 (81.5)	4 (10.5)	12 (31.5)	13 (34.2)
1989	19	10 (52.6)	9 (47.4)	17 (89.4)	16 (84.2)	2 (10.6)	4 (21.0)	4 (21.0)
1990	25	14 (56.0)	11 (44.0)	22 (88.0)	23 (92.0)	3 (12.0)	8 (32.0)	6 (24.0)
1991	30	13 (43.3)	17 (56.6)	28 (93.3)	26 (86.6)	2 (6.6)	13 (43.3)	7 (23.3)
1992	53	23 (43.3)	30 (56.7)	47 (88.6)	47 (88.6)	6 (11.4)	18 (33.9)	23 (43.3)
1993	58	32 (55.1)	26 (44.9)	54 (93.1)	54 (94.8)	4 (6.9)	23 (39.6)	19 (32.7)
1994	41	18 (43.9)	23 (56.1)	38 (92.6)	39 (95.1)	3 (7.4)	28 (68.2)	23 (56.0)
1995	37	18 (48.6)	19 (51.3)	36 (97.2)	32 (86.4)	1 (2.8)	14 (37.8)	16 (43.2)
1996	21	12 (57.1)	9 (42.8)	21 (100)	19 (90.4)	0	12 (57.1)	12 (57.1)
1997	43	24 (55.8)	19 (44.1)	42 (97.6)	39 (90.6)	1 (2.4)	23 (53.4)	36 (83.7)
1998	23	12 (0.52)	11 (47.8)	20 (86.9)	22 (95.6)	3 (13.1)	12 (52.1)	18 (78.2)
Total	s	196 50.6 %	192 49.4 %	357 92.0 %	348 89.6 %	29 7.4 %	46 11.8 %	177 45.6 %

Table I. – Data of patients from Group I, based on the Jones’ criterions
Ch.minor - chorea minor, N.subcut. – nodules subcutaneous, E.margi. – erythemamarginatum

Data from Table 1 shows decreasing number of patients in the end of 80^s and, increasing of the number in the beginning of last decade, with peak of incidence in 1993.

	N. patients	Arthritis	Carditis	Ch. minor	S. murm. Card/Ch.m	D. murm. Card/Ch.m
1988	38	32	31	4	26+1	9+0
1989	19	17	16	2	14+0	4+0
1990	25	22	16	3	12+0	2+0
1991	30	28	26	2	23+0	7+0
1992	53	47	47	6	40+1	11+0
1993	58	54	54	4	50+0	18+0
1994	41	38	34	3	28+1	3+1
1995	37	36	32	1	32+0	5+0
1996	21	21	19	0	17+0	3+0
1997	43	42	32	1	29+0	7+0
1998	23	20	22	3	22+1	4+0
Total	388 100 %	357 92.0%	338 87.1%	29 7.4 %	293+4 75% +1%	63+1 16.2%+02%

Table 2. Children who had developed systolic and diastolic murmur in comparison with children who has a three dominate Jones’ criterions. Ch. Minor – chorea minor, S. murm – systolic murmur, D. murm. – diastolic murmur, Card/Ch.m – carditis/chorea minor.

In both groups incidence of the carditis and other Jones' criteria are equal and, basing on the clinical findings (ECG, X-ray chest and especially cardiological findings of the murmurs) in the Group I and, echocardiographic findings in the Group II we think that the lesion are as well equal (in Group I, 62% has a systolic murmur while in Group II, 61.53% had mitral regurgitation).

	N. of patients	Male N (%)	Female N (%)	Arthritis N (%)	Carditis N (%)	Ch. Minor N (%)	Erymarg N (%)
1999	14	8 (64.2)	6 (42.8)	14 (100)	12 (85.7)	0 (0)	4 (28.7)
2000	30	16 (53.3)	14 (46.7)	28 (93.3)	24 (72.0)	2 (6.6)	6 (6.6)
2001	43	20 (46.5)	23 (53.5)	42 (97.6)	40 (93.0)	1 (2.3)	7 (16.2)
2002	33	17 (51.5)	16 (45.5)	33 (100)	30 (90.9)	0 (0)	6 (18.1)
2003	18	10 (55.5)	8 (44.5)	16 (88.8)	16 (88.8)	2 (11.1)	6 (33.3)
2004	11	5 (45.4)	6 (63.6)	10 (90.9)	11 (100)	1 (9.0)	4 (36.3)
2005	9	4 (44.5)	5 (55.5)	9 (100)	9 (100)	0 (0)	2 (22.2)
2006	11	4 (36.4)	7 (63.6)	9 (81.8)	9 (81.8)	2 (18.1)	2 (18.1)
2007	14	6 (42.8)	8 (57.2)	13 (92.8)	13 (92.8)	1 (7.14)	2 (14.2)
2008	16	7 (43.7)	9 (56.3)	14 (87.5)	15 (93.3)	2 (12.5)	3 (18.7)
2009	8	4 (50.0)	4 (50.0)	7 (87.5)	7 (87.5)	1 (12.5)	2 (25)
2010	14	6 (42.8)	8 (57.2)	12 (85.7)	12 (85.7)	2 (14.2)	2 (14.2)
Total	221 100 %	107 48.4 %	114 51.6 %	207 93.6 %	198 89.5 %	14 6.3 %	46 20.8 %

Table 3. Manifested Jones' criteria in patients treated in period 1999 – 2010. Ch. minor - chorea minor, Ery. marg – Erythema marginatum,

	N. of patients	Carditis N	Mitr. st. N %	Mitr. ins. N %	Ao. inss. N %	Ao. st. N %	Tr. ins. N %
1999	14	12	2 14.2	8 57.1	2 14.2	0 0	2 14.2
2000	30	24	4 13.3	16 63.3	3 10.0	0 0	2 6.6
2001	43	40	6 13.9	28 65.1	7 16.2	1 2.3	3 6.9
2002	33	30	2 6.0	22 66.6	4 12.2	2 6.0	1 3.0
2003	18	16	2 11.1	12 66.6	3 16.6	0 0	1 5.5
2004	11	11	3 27.2	8 72.7	4 36.3	0 0	0 0
2005	9	9	2 22.2	6 66.6	2 22.2	0 0	2 22.2
2006	11	9	2 18.1	6 54.5	3 27.2	0 0	0 0
2007	14	13	3 21.4	8 57.1	2 14.2	0 0	0 0
2008	16	15	2 12.5	8 50.0	0 0	0 0	0 0
2009	8	7	0 0	6 75.0	0 0	0 0	0 0
2010	14	12	2 14.2	8 57.1	1 7.1	0 0	1 7.1
Total	221	198 89.59%	29 13.12%	136 61.53%	31 14.0%	3 1.35%	12 5.42%

Table 4. Group II – patients with carditis and lesion of the heart valves; Mitr.st. – mitral stenosis, Mitr. ins. – mitral insufficiency, Ao.inss – aortic insufficiency, Ao.st – aortic stenosis, Tr. Ins. – tricuspid insufficiency

The important murmurs in children with acute rheumatic fever and presented carditis are the apical holosystolic murmur of mitral incompetence, the early decrescendo murmur of aortic incompetence and mid-diastolic murmur at the apex (the Carey-Coombs murmur). Most frequent is the soft mitral regurgitant murmur and, this may be pansystolic, or it may peak during late systole. The intensity and the duration of this murmur can wane towards recovery. (11, 12) In our study in acute stadium of rheumatic fever, 75% of children with carditis and, 1% with chorea minor manifested systolic murmur. Three months later this number has been decreased at 62%.

Discussion

The advent of echocardiography has paved the way for a clearer understanding of the pathophysiological findings observed in the hearts of patients with rheumatic fever. Results from this diagnostic modality have shown that as many as three-fifths of patients without clinical evidence of carditis had significant findings of mitral valvar prolapse, annular dilation, chamber enlargement and multiple valvar regurgitation. (13, 14)

Echocardiography as a method for evaluation of cardiac problems (congenital anomalies and lesion of rheumatic fever) in our Division started improving from September 1999. In our study, we noted that from 221 patients with acute rheumatic fever, 198 or 89.59 % manifested echocardiographic parameters of carditis. Diagnosis was based in the value of dimensions of the left ventricle and value of fractional shortening or the ejection fraction using Teichholz method of calculation. All children with carditis manifested FS fewer than 0.28. In 28 patients, with signs of heart failure we measured FS from 0.16 to 0.21, where 7 of them died, in acute period.

Carditis is the most common serious manifestation of the acute rheumatic process, since it is the only one that causes death during the acute attack or produces residual disability and late mortality. Carditis is seen in up to half of patients with rheumatic fever and it is the most clinical findings as a cause for admission to hospital. (15, 16, 17) In both our Groups incidence of carditis is equal and much higher than other statistical data: in 348 children (89.6 %) out of 388 in Group I and 198 (89.5%) out of 221 children in Group II. In the other side, basing in the still low level of social and health care, it is rule in our institution for hospitalization all patients with rheumatic fever, where in our study polyarthritis and chorea minor were more often manifestations for hospitalization.

Rheumatic carditis is a pancarditis and cardiac failure is usually the result of the associated myocarditis. (18) In our study 21 patients (6.0%) out of 348 with carditis from Group I, manifested at admission clinical signs of heart failure, while 38 (19.1%) out 198 from Group II. 4 patients from Group I and 3 from Group II died during the first 10 days of hospitalization, with signs of congestive heart failure. 2 children from Group II developed several lesion on the mitral valve with high level of insufficiency and, in the inability for surgical correction, died with signs of heart failure and pulmonary edema.

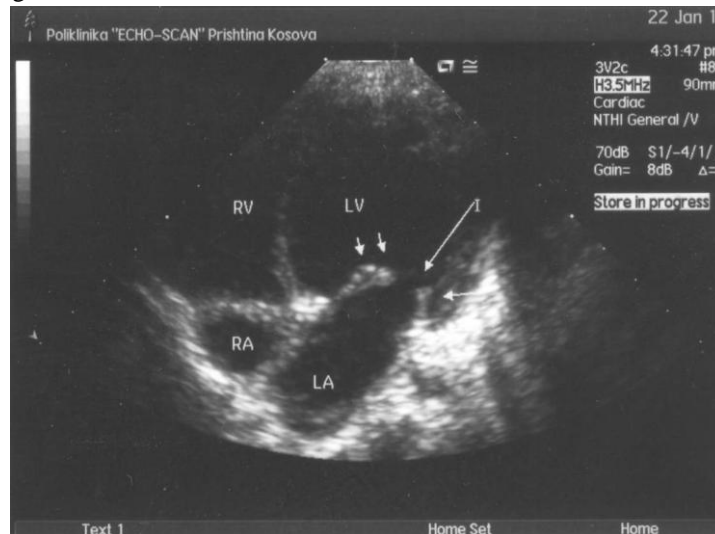
The classic findings of rheumatic mitral stenosis involve thickening and fusion of the mitral valve commissural edges and chordae. This result in characteristic abnormalities of the mitral leaflet opening motion and due to commissural fusion, the leaflets open with a “doming” motion. The degree of chordal thickening and mitral valve commissural fusion is highly variable. In rheumatic heart disease, the open anterior leaflet has also been described as having “hockey stick” appearance. (19, 20, 21) Initially, this results in reduction of the orifice and conversion of the mitral leaflet-chordal apparatus from a tubular channel to a tunnel – shaped orifice. But all these changes we can register in later stages of the disease. There is a continuum between upper limit of physiological and pathological regurgitations, usually graded by a cardiologist. (22, 23, 24) In our study, in the acute stage of the disease, echocardiographic signs of mitral stenosis manifested 29 patient or 13 %. Many of these had borderline 1-2 centimeters mitral regurgitant jets but did not meet defined pathological Doppler criteria. Mitral regurgitation (MR) is a commonly encountered morphologic and hemodynamic lesion in patients with rheumatic fever. In our study 136 children (61.5%) from 221 manifested MR. For complete hemodynamic evaluation of MR we used the full range of echocardiographic techniques, especially color Doppler imaging which was the primary echocardiographic tool for detection and quantification of MR. In the determination of the severity of MR we used continual wave and color Doppler imaging. We used the average value of three measurements, indexing the regurgitation jet area to left atrial size. From 132 of our patients with MR, 28 had trivial, 62 had medium and 42 had severe MR.

In future, fewer individuals with borderline regurgitation would need cardiology referral. The absence of universally accepted diagnostic criteria for rheumatic heart disease, in particular the morphological features, presents challenges for clinicians involved with rheumatic heart disease screening and diagnosis. There is some agreement that both morphological features and pathological grade regurgitation need to be present for echocardiographic diagnosis of rheumatic heart disease, but our analysis supports the use of more stringent Doppler criteria than were used in earlier studies. Further studies to achieve international standardization are required. (9, 25, 26)

The most common cause of acquired aortic valve disease in children and adults in underdevelopment countries is rheumatic fever. The cusps are thickened and exhibits restricted mobility (see: Figure 1). (27) In our study 31 patients manifested aortic insufficiency, and 24 of them manifested hemodynamic importance. Only 3 patients were presented with trivial aortic stenosis.

The tricuspid valve is rarely included in rheumatic fever and can be manifested as stenosis or regurgitation. We noted trivial tricuspid regurgitation in 12 patients and none of them with stenosis.

Figure 1. Thickened mitral valve three months after rheumatic disease.



Limitations

We presented only data of patients which have been treated in our Institution, but real number could be much higher, basing in the fact that Albanian community during the period 1992-1999 boycotted new health institutions organized by Serbians. During the next four years (1992 – 1994) thousands Albanians migrated in the West Europe and started supporting their families in Kosova. Despite of decreasing incidence in the next four years, presented statistical data showed that rheumatic fever remains still the highest in Europe. In this period we still didn't have echo machine to perform echocardiography and, this was the reason why we didn't have evaluation of heart lesion and, exact data of type and level of disability of the valves.

The tendency of increasing the incidence is present in period 1999 – 2001, despite of them that we don't have real data during the 1999, where war was in Kosova. This can be disserted as a consequence of the war, migration of the population from and to the Kosovo, destroyed of the infrastructure and poor health care service.

There are several technical factors that must be accounted for determining anatomic orifice size from this approach. We used two-dimensional echocardiography to visualize the actual restrictive orifice of the stenotic mitral valve and its limiting orifice. We also used Doppler echocardiography to determine the transvalvular gradient from left atrium to the left ventricle, using the continuous wave Doppler and color Doppler. In our study it was one of the most important factors in determining severity of mitral stenosis and relation-ship to the patient's functional status.

Conclusion

Despite results of economic development and increasing level of social and health services Kosova still remains one of the most underdevelopment countries in Europe, where Chronic diseases e.g.,cystic fibrosis, seasonal enterocolitis, tuberculosis and rheumatic heart disease overload the public health system and contribute to the high morbidity and mortality in these disease states. The number of the affected children with rheumatic fever remains still high, especially during the last war, while, more of them as a consequence left disable of heart lesion. In last decade we started applied echocardiography as a diagnostic method in evaluation and assessment of the carditis and heart lesion. In 1995 Veasy, proposed that Doppler evidences for mitral and aortic regurgitations be included as one of the minor manifestations in the revised Jones' criterions provided that rigid echocardiographic rules are employed. (6, 8, 10) Analysis of current data on the use of echocardiography has made Narulla and colleagues move one step further and in 1999 they concluded that the echocardiography and Doppler imaging may have a place as a major criterion in the Jones's criterions. Implementation of this modification to the Jones' criterions may not be practicable at this point in developing countries unless prospective well-controlled studies are done that demonstrate distinctly superior treatment and prognostic value of detecting carditis in this manner. (25, 26) In developing countries exit opportunity for this proposes but, basing on the recent published data and on our experience and results we support this propose.

References

1. American Heart Association 1977; Committee on rheumatic fever and bacterial endocarditis. Prevention of rheumatic fever; *Circulation* 55:1.
2. Dajana A, Allen AD, Taubert KA 1993; Echocardiography for diagnosis and management of rheumatic fever. *Journal of the American Medical Association* 269: 2084 – 2093.
3. Harrison MR, Gurley JC, Smith MD, et al. A practical application of Doppler echocardiography for the assessment of severity of the aortic stenosis; *Am Heart Journal*, 1988; 115:622 - 628.
4. Jones TD 1944 Diagnosis of rheumatic fever: *Journal of the American Medical Association*, 126: 481 - 484.
5. Jones Criteria (Revised) 1984 for guidance in the diagnosis of rheumatic fever. *Circulation* 69: 203A - 208A.
6. Veasy LG 1995; Rheumatic fever - T. Duchett Jones and the rest of story; *Cardiology in the Young* 5: 293 – 301
7. Rachel H. Webb, Nigel J. Wilson, Diana R. Lennon, Elizabeth M. Wilson et al. Optimizing echocardiographic screening for rheumatic heart disease in New Zealand: not all valve disease is rheumatic, *Cardiology in the Young*, 5:436 -443, 2011.
8. Willson NJ, Neutze JM 1995; Echocardiographic diagnosis of subclinical carditis in acute rheumatic fever. *International Journal of Cardiology* 50: 1 - 6.
9. Thomas L Foster E, Hoffman JI, et al. The Mitral Regurgitation Index: an echocardiographic guide to severity. *J Am CollCardiol* 1999; 33:2016 – 2022.
10. Feigenbaum's Echocardiography, sixth edition, 2005; Lippincot Williams & Wilkins
11. American Heart Association. "Rheumatic Heart Disease/Rheumatic Fever". Retrieved 2008-02-17.
12. Abbas, Abul K.; Lichtman, Andrew H.; Baker, David L.; et al (2004). *Basic immunology: functions and disorders of the immune system* (2 ed.). Philadelphia, Pennsylvania: Elsevier Saunders.

13. Kumar, Vinay; Abbas, Abul K.; Fausto, Nelson; & Mitchell, Richard N. (2007). Robbins Basic Pathology (8th ed.). Saunders Elsevier. pp. 403-406
14. Cilliers AM. Rheumatic fever and its management. *BMJ*. Dec 2 2006; 333(7579):1153-6.
15. Shulman ST. Rheumatic heart disease in developing countries. *N Engl J Med*. Nov 15 2007; 357(20):2089; author reply 2089.
16. Carapetis JR, McDonald M, Wilson NJ. Acute rheumatic fever. *Lancet*. 2005; 366:155-68.
17. Erdem G, Mizumoto C, Esaki D, Reddy V, Kurahara D, Yamaga K, et al. Group A streptococcal isolates temporally associated with acute rheumatic fever in Hawaii: differences from the continental United States. *Clin Infect Dis*. Aug 1 2007; 45(3):e20-4.
18. Carapetis JR. Rheumatic heart disease in developing countries. *N Engl J Med*. Aug 2 2007; 357(5):439-41.
19. Weiner SG, Normandin PA. Sydenham chorea: a case report and review of the literature. *Pediatr Emerg Care*. Jan 2007; 23(1):20-4.
20. Marijon E, Ou P, Celermajer DS, Ferreira B, Mocumbi AO, Jani D, et al. Prevalence of rheumatic heart disease detected by echocardiographic screening. *N Engl J Med*. Aug 2 2007; 357(5):470-6.
21. Marijon E, Ou P, Celermajer DS, Ferreira B, Mocumbi AO, Sidi D, et al. Echocardiographic screening for rheumatic heart disease. *Bull World Health Organ*. Feb 2008; 86(2):84.
22. Vijayalakshmi IB, Vishnuprabhu RO, Chitra N, Rajasri R, Anuradha TV. The efficacy of echocardiographic criteria for the diagnosis of carditis in acute rheumatic fever. *Cardiol Young*. Oct 10 2008; 1-7.
23. Narula J, Kaplan EL. Echocardiographic diagnosis of rheumatic fever. *Lancet*. Dec 8 2001; 358(9297):2000.
24. Tubridy-Clark M, Carapetis JR. Subclinical carditis in rheumatic fever: a systematic review. *Int J Cardiol*. Jun 25 2007; 119(1):54-8.
25. Lopez-Benitez JM, Miller LC, Schaller JG, Moreno LM, de Canata ME. Erroneous diagnoses in children referred with acute rheumatic fever. *Pediatr Infect Dis J*. Feb 2008; 27(2):181-2.
26. Ayoub EM, Nelson B, Shulman ST, Barrett DJ, Campbell JD, Armstrong G. Group A streptococcal antibodies in subjects with or without rheumatic fever in areas with high or low incidences of rheumatic fever. *Clin Diagn Lab Immunol*. Sep 2003; 10(5):886-90.
27. Pereira BA, da Silva NA, Andrade LE, Lima FS, Gurian FC, de Almeida Netto JC. Jones criteria and under diagnosis of rheumatic fever. *Indian J Pediatr*. Feb 2007; 74(2):117-21