

The Clinical Syndrome of Subileus due to Appendicular Artery Thrombosis (In Child)
(Case study)



Healthcare

Key words: subocclusion, arterial thrombosis, appendicitis, rectal examination, enterococcus.

Petraq Mustaqe

VLORA Regional Hospital ALBANIA
Faculty of Medical Technical Sciences, Elbasan, Albania.

Abstract

This is the complicated case of an 18-month child entering the regional hospital of Vlore with signs of intestinal obstruction, initially with abdominal pains, vomits, distinct meteorism and last defecation with liquid content in cherry color. Considering the medical tests results (leukocytosis 22.000), the abdominal roentgenography with central hydroaeric levels, the continuous pain and the last rectal examination showing a liquid content in cherry color, after an extended consultation, the case was evaluated as an ileocecal invagination with signs of initial peritonism. However, the laparotomy showed gangrenous acute appendicitis (appendicitis acuta gangrenosa) with thrombosis of appendicular artery. The best solution for this case, following a full review of the abdomen, was that of a typical appendectomy. The histological examination confirmed the appendicular artery thrombosis. Enterococcal infection. Such complicated clinical cases have been considered even by other others.

Case presentation

An 18-month child called D.M, with abdominal pains and vomits appeared at the pediatric ward on 04 August 2011 for the serious reason that the child's defecation contained small quantities of liquid matter in cherry color.

The laboratory examination resulted in leukocytosis 22.000 per mm³ with granulocytosis 93%. The child was in really poor conditions: intoxicated, 37 C degree body temperature, distinct meteoric abdomen, adipose, no effect of common sedatives on the continuous pain.

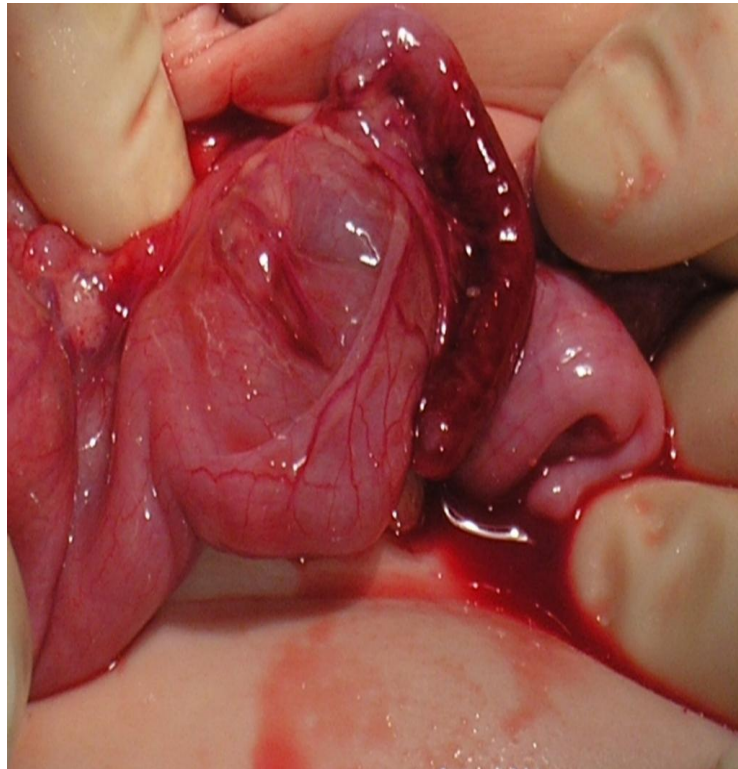
The echographic examination showed no visible signs except for the distinct meteorism of the small intestine.



Photo 1. Direct abdominal ro-graphy with numerous central levels

Results of the clinical examination: painful and meteoric abdomen, continuous vomits since 12 hours, right abdominal region particularly sensible and with peritonism. Empty ampulla in rectal examination, however at this moment it presents thin liquid in cherry color, the same liquid showed in the next photo, following laparotomy.

In conclusion, considering the above, the surgical evaluation is as follows: Acute intestinal occlusion. Invagination. It was decided for an emergent laparotomy. The results of the laparotomy: Thrombosis of appendicular artery. Acute appendicitis



The case is showed in photo 2.

It was treated as a case of acute appendicitis with subileus phenomena from microbial intoxication after thrombosis of appendicular artery and display of distinct inflammatory phenomena of gangrenous acute appendicitis.

Following a three-day treatment with broad-spectrum antibiotics, liquids, common sedatives, antipyretics, the child is dismissed in good conditions, surgical wound closed *per primam intentionem*.

Appendix subjected to histopathological and microbial examination. All the remaining signs were recovered within the first 48 hours.

Case Analysis

The acute appendicitis is recognized through thrombosis of appendicular artery (1,3,4,6,7)

Furthermore, we pointed out that paralytic occlusion may result either from arterial or venous acute thrombosis, or from inflammatory abdominal processes, especially enterococcus, or from rapid neuroreflecotry, neurohumoral or metabolic changes (intoxication, diabetes, thrombosis of basic feeding vases) (1,2,5,7)

In this case, laparotomy was instructed for an ileocecal invagination although in palpation no mass was found; however, considering the cherry color of the liquid in rectal examination, it was first decided for the above diagnosis.

After all, the most important thing is to resolve the case and to make all the efforts for getting closer to the real diagnosis...

The anatomopathological report led to necrosis of the tissue cells of the appendix and superposition of the enterococcus in an inflammatory process.

References

1. Wilmore & co. A C S Surgery Principles & Practice 2003 261-279.
2. N.Kacani & co. Semundjet kirurgjikale Tirane 2006 fq. 157-188.
3. Wacha.H, & co. Risk factors associated with intraabdominal infections; a prospective multicenter study. Langebecks Arch SURG. 1999, 384; 24-32.
4. Wilson S.E, & CO. Impact of anatomical site on bacteriological and clinical outcome in the management of intrabdominal infections. Am.Surg. 1998 64;402-407.
5. Christou.N.V, & co. Surgical infection Society intraabdominal infection study; prospective evaluation of management techniques and outcome. Am. Surg.1993 128; 193-198.
6. Burnett R.J. & co. Definition of the role of enterococcus in intraabdominal infection; analysis of a prospective randomized trial. Surgery 1995 118; 716-721.
7. Barie.P.S & co Pathogenicity of the enterococcus in surgical infections. Am. Surg. 1990 212; 155-159.